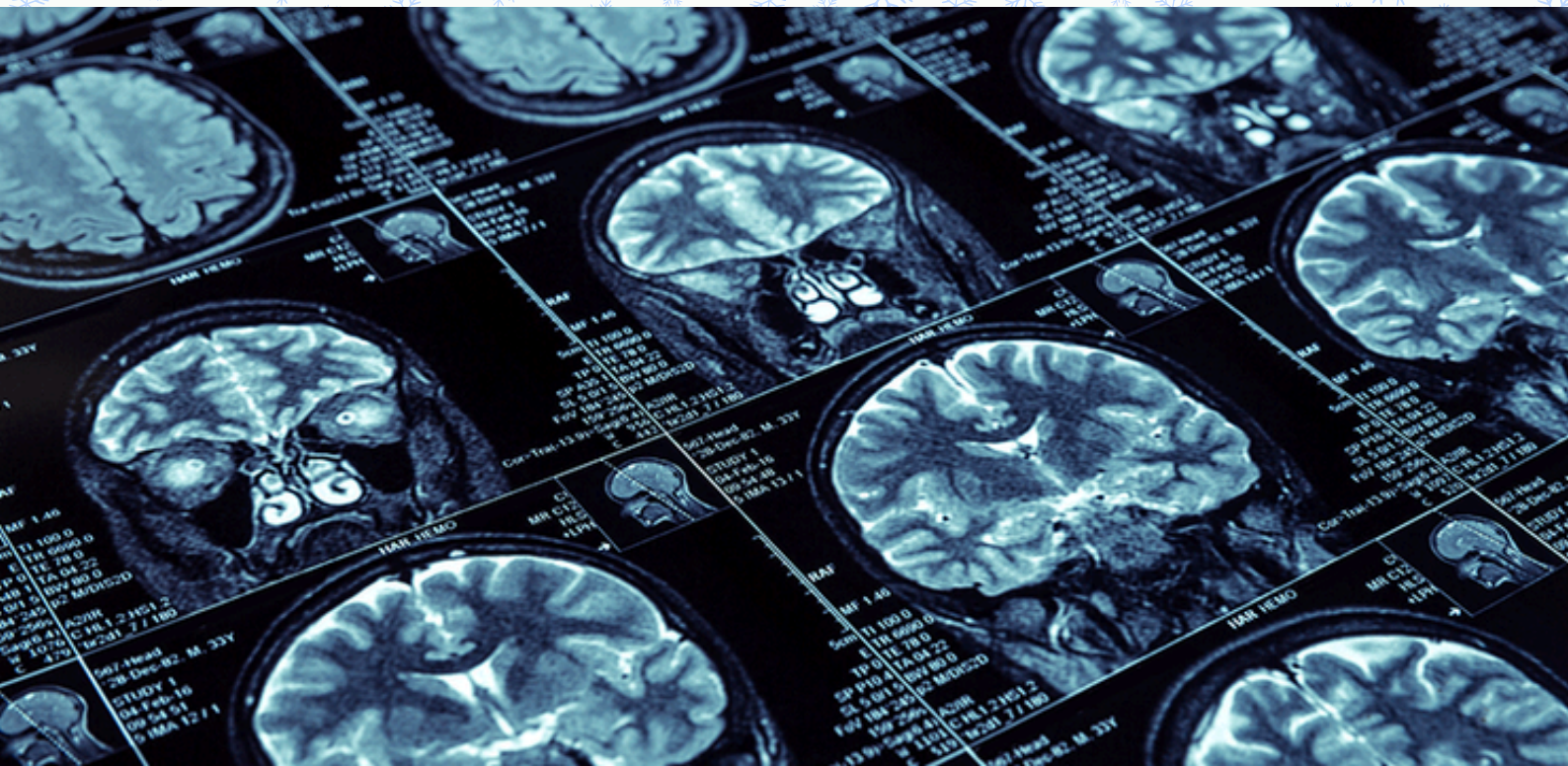

# Neurobulletin



WINTER 2025

Dandy Netherlands Neurosurgical Club



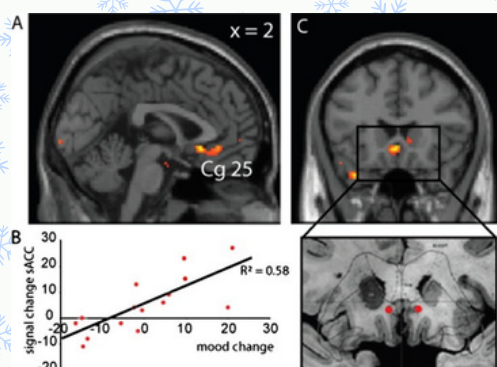
## WINTER CASE

(Mayberg 2005, McNeely 2008)

Gracia, a 45-year-old woman, has been suffering from severe, recurrent major depressive disorder since her early teens. Despite years of pharmacological treatment with multiple antidepressants, electroconvulsive therapy, and psychotherapy, her symptoms persist. Functional imaging showed hyperactivity in the subgenual cingulate cortex (Brodmann area 25), a region implicated in mood regulation and affective processing.

Following multidisciplinary evaluation, she underwent bilateral Deep Brain Stimulation (DBS) of the subgenual cingulate cortex (Cg25). Under stereotactic MRI guidance, electrodes were implanted in the white matter adjacent to Cg25 and connected to an implantable pulse generator placed subcutaneously in the chest. Stimulation parameters were gradually optimized postoperatively to achieve modulation of the hyperactive limbic-prefrontal network.

Within three months, Gracia showed marked clinical improvement. Her Hamilton Depression Rating Scale score decreased by 55%, indicating partial remission. She reported restored motivation, improved sleep, and resumed social functioning. Although still considered experimental, DBS targeting Cg25 demonstrates the potential of neuromodulation to restore network balance in patients with treatment-resistant depression.



## IN THIS ISSUE:

WINTER CASE: CG25 DBS

NEUROSURGEON THROUGH HISTORY: BEN CARSON

HIFU IN NEUROSURGERY

MEET THE BOARD: ERIC

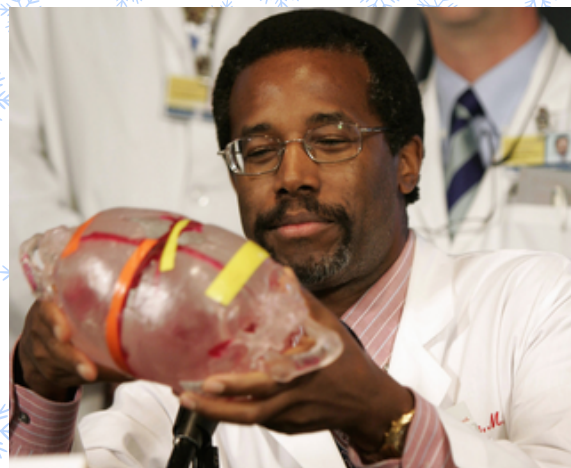QUIZ & ANSWERS

RECAP: THE FIRST TWO LECTURES OF THE YEAR

UPCOMING EVENT

## Ben Carson: From Humble Beginnings to the Frontiers of Pediatric Neurosurgery

Dr. Benjamin Solomon Carson is regarded as one of the foremost pioneers of pediatric neurosurgery, not only has he pushed the boundaries of what could be achieved in the pediatric brain but he also became a symbol of perseverance through hardship. From his humble upbringing in inner-city Detroit to leading the neurosurgical division at Johns Hopkins, his life represents a praiseworthy combination of perseverance and surgical brilliance, one that redefined what was surgically possible in the brains of the youngest and most vulnerable patients.



### Early Life and Education

Ben Carson was born on September 18th, 1951 in Detroit, Michigan, to Sonya and Robert Carson who were both migrants from rural Georgia (USA). His mother, who had only a third-grade education, worked multiple jobs to support her two sons after separating from her husband when Ben was eight years old. Growing up in poverty and often struggling academically, Carson's early years did not foreshadow the surgeon he would become at all. Yet, Sonya Carson instilled in her sons a rigid sense of discipline, faith, and self-education. She told them that if they can read, they can learn just about anything, a dictum that would later become the moral foundation of Carson's philosophy. She restricted television time, required her sons to read two books a week and submit written summaries, a routine Carson later credited for sparking his intellectual awakening.

Carson's early academic record was poor; classmates teased him for his grades, and teachers viewed him as a lost cause. Yet under his mother's insistence that he read two library books per week and write handwritten summaries, his performance improved markedly. By high school, Carson excelled academically and earned a full scholarship to Yale University, where he studied psychology. There he explored cognitive science, neurology, and behavior. After graduating, he attended the University of Michigan Medical School, initially intending to become a psychiatrist but soon drawn to the hands-on precision of neurosurgery. His natural dexterity, quiet temperament, and ability to remain calm under extreme stress caught the attention of his mentors, who encouraged him toward neurosurgery.

### Neurosurgical Residency at Johns Hopkins and Early Surgical Innovations

Carson began his neurosurgical residency at Johns Hopkins Hospital in 1977 under the mentorship of Dr. Donlin Long and Dr. John M. Freeman, both influential figures in the development of neurosurgical and pediatric epilepsy programs at Johns Hopkins.

Hopkins at that time was one of the few centers pioneering surgical treatments for childhood epilepsy, hydrocephalus, and congenital malformations. Carson's residency coincided with an era of transformation in neurosurgery, as microsurgical tools and imaging advances redefined what was surgically possible. During residency, Carson gained substantial experience in pediatric neurosurgical care, particularly hydrocephalus and epilepsy surgery, and was exposed to the evolving integration of microsurgical tools and neurophysiological monitoring. Colleagues described his technical promise and composure during demanding operations. His early academic work, which later included contributions to cranial and craniofacial pathologies, grew from this foundational period at Johns Hopkins. After completing his residency and a brief fellowship in Australia, Carson returned to Johns Hopkins in 1984. At just 33 years old, he was appointed Director of Pediatric Neurosurgery, becoming the youngest chief of a major neurosurgical division in the United States.

### Functional Hemispherectomy: Redefining Pediatric Epilepsy Surgery

One of Carson's earliest and most enduring contributions was the refinement of functional hemispherectomy, used to treat children suffering from epilepsy due to Rasmussen's encephalitis, cortical dysplasia, or hemimegalencephaly. Traditional anatomical hemispherectomy involved total resection of one cerebral hemisphere and carried high rates of hemorrhage, hydrocephalus, and mortality. Carson came up with a disconnection-based approach, where pathological cortical areas were functionally isolated rather than entirely removed. He introduced staged disconnections of the corpus callosum and internal capsule while preserving deep vascular and ventricular structures. His innovations; the use of meticulous hemostasis, intraoperative ventricular drainage, and improved cortical mapping, dramatically reduced complication rates and improved long-term seizure control. Carson's pioneering work on functional hemispherectomy, later detailed in publications throughout the 1990s, demonstrated significantly improved outcomes compared with traditional anatomical hemispherectomy.

His disconnection-based approach, first applied in children with catastrophic epilepsy such as Rasmussen's encephalitis, achieved substantial seizure control while preserving motor and language function. These contributions established functional hemispherectomy as a cornerstone of modern pediatric epilepsy surgery.

### **Advances in Craniofacial and Skull-Base Surgery**

Carson also transformed craniofacial and skull-base neurosurgery. He developed refined operative techniques for craniosynostosis, Chiari malformations, encephaloceles, and congenital cranial dysmorphisms, utilizing multidisciplinary collaboration among neurosurgeons, plastic surgeons, and anesthesiologists.

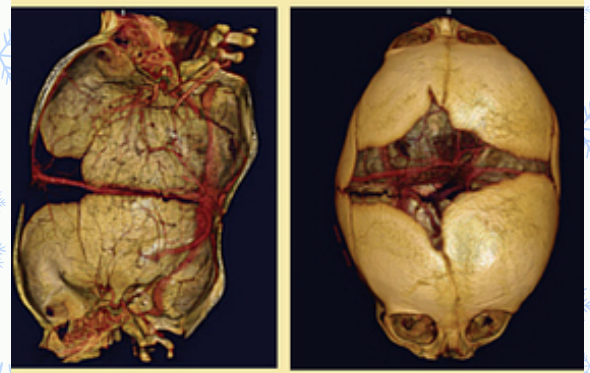
He introduced preoperative 3D imaging for surgical planning, used microsurgical tools adapted for pediatric bone and soft tissue, and advocated for early intervention to prevent neurodevelopmental delay. Under his direction, the Johns Hopkins craniofacial program became a global model for interdisciplinary pediatric care.

### **The Binder Twins: A 22-Hour Leap of Faith and Global Recognition**

Carson achieved worldwide recognition in 1987 when he led a seventy-member multidisciplinary team, preceded by months of anatomical study and computer modeling, in the historic separation of the Binder craniopagus twins. The operation lasted twenty-two hours and involved the innovative use of hypothermic circulatory arrest, microsurgical dissection under an operating microscope, and stepwise venous separation into pediatric neurosurgery.

Although the twins ultimately suffered many neurological complications, it was the first time in history that craniopagus twins joined at the occipital region had been separated with both surviving the operation. The procedure demanded not only anatomical precision but also groundbreaking interdisciplinary coordination among neurosurgeons, anesthesiologists, cardiovascular surgeons, and plastic reconstructive teams. Though the twins later suffered neurological deficits, the operation's technical success marked a watershed moment for both pediatric neurosurgery and global surgical collaboration. Carson integrated microsurgical vascular techniques and stereotactic mapping to navigate the shared venous sinuses, all while preserving critical cortical structures. The success established Carson globally in complex pediatric craniofacial and vascular neurosurgery. The procedure introduced several innovations that have since become standard: multidisciplinary preoperative simulation and 3D vascular modeling, intraoperative angiographic monitoring, and surgical pacing being more usually guided by physiological stability rather than arbitrary time limits.

Over the next decade, Carson would lead or advise in many major craniopagus separation cases worldwide, including the successful 1997 operation on Zambian twins Luka and Joseph Banda. His cumulative experience helped in shaping modern protocols for craniopagus twin separations. Despite his growing fame, Carson remained closely involved in patient care and education, training many residents and fellows in microsurgical and craniofacial techniques.



### **Later Career and Legacy**

By the 1990s and early 2000s, Carson's department at Johns Hopkins had become one of the leading pediatric neurosurgical units in the world. He contributed over 120 peer-reviewed papers and book chapters, including works on congenital malformations, brainstem tumors, and hemispheric disconnection techniques.

In 1990, Carson published his autobiography *Gifted Hands*, which became an international bestseller and later a film adaptation. The book presented his life as both an educational and moral journey, from hardship to excellence through discipline, belief and perseverance. His humanitarian work included establishing the Carson Scholars Fund, which provided scholarships to underprivileged youth across the United States. In 2008, Carson received the Presidential Medal of Freedom, the highest civilian award in the United States, for his contributions to medicine and humanitarian service. Although his later entrance into politics and public debate drew controversy, his legacy in neurosurgery remains uncontested.

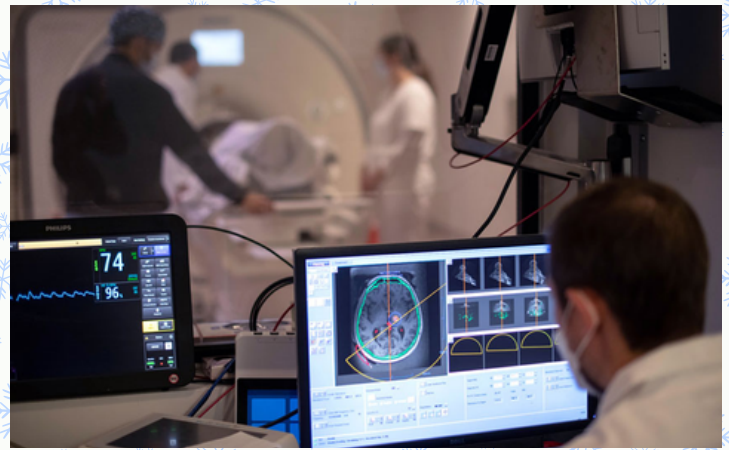Drawing on themes he frequently expressed during his years at Johns Hopkins, Carson described the brain as a God-given vessel of human potential. To heal it, he believed, was to return a child's capacity to grow, learn, and dream. Through his hands, many children recovered that potential.



**WRITTEN BY:  
AKIN SÖNMEZDAĞ**

## HiFU in Neurosurgery

Functional disorders in the central nervous system, also known as functional neurological disorders, have variable etiologies and symptomatic patterns and can be of great impact in someone's daily living. Therefore, treatments are desperately needed for these patients. Functional neurological disorders that are untreatable by medications or other earlier lines of treatment can be managed through surgery. Some known surgeries are DBS, stereotaxic lesions and radiosurgery. These however, are invasive and complicated.

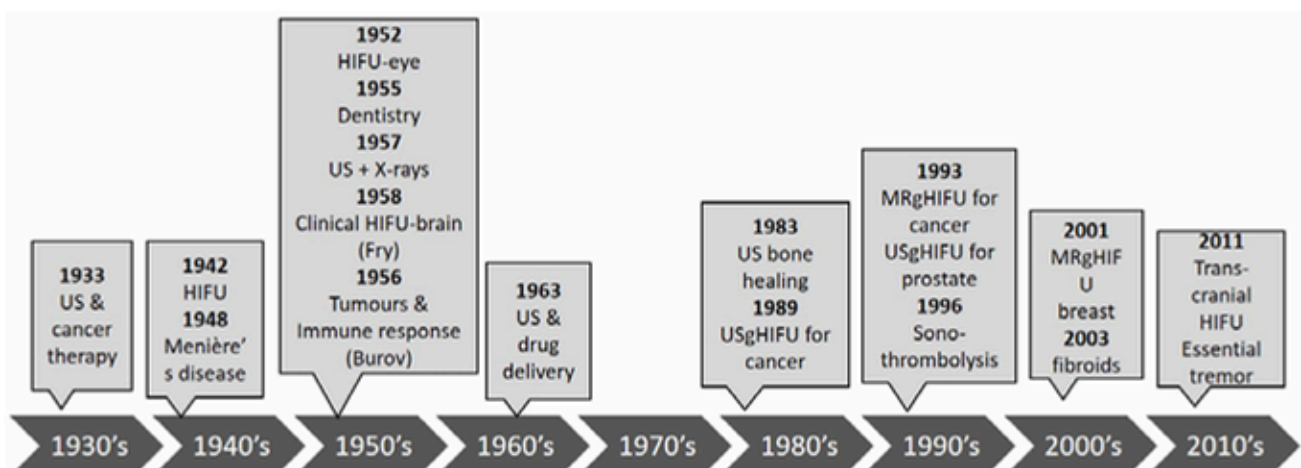


### History of HiFU

In the last couple of years, an intervention was rediscovered in treating functional neurological disorders like essential tremor. Its use goes back far into the 20th century. In 1927, ultrasound energy was described by Wood & Loomis without any indication for its therapeutic potential.

Its capability to tightly focus into volumes with distance from the source was used in many diverse processes, ranging from sonophoresis (improved delivery of drugs through the skin) to cancer therapies. In 1947, William and Francis Fry designed the focus piezoelectric transducers that would refine the precision in which the ultrasound beam was targeted.

In 1953, a team under Dr. Petter Lindström conducted a study on intractable pain in 17 cancer patients in whom they exposed the brain to a high frequency ultrasound through an opening in the calvaria. A complete relief of pain was reported in 10 patients and a decrease in pain in 5 patients. Post-mortem brain analyses showed minimal damage in other tissues aside from the lifted dural flap where the ultrasound was done. Lindström noticed the importance of keeping the head stationary and thus created the stereotactic frame with his colleague Leksell. This research has initiated the further focus of HiFU in the neurosurgical field. Later on, the limitation of its necessity to create an opening in the skull was diminished through technical advances. Enabling transcranial sonication, its use in malignant glioma and neuropathic pain treatments was found.



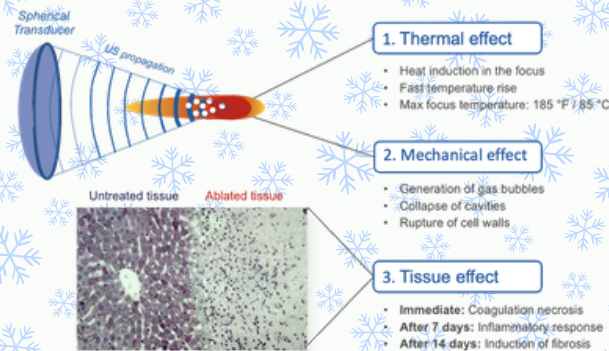
## Mechanisms and principles of HiFU

MRgHiFU works through the concentration of high-energy ultrasound waves into the tissue inducing a local thermal ablation. Piezoelectric transducers focus this into the localized tissue of interest, where the lesioned location will be called the “focal zone”. Here, the ultrasound intensity ranges from 100-10.000 W/cm<sup>2</sup>. Its size depends on the temperature reached and the duration of the exposure. Not only thermal ablation, but a cascade of biological reactions is induced by the ultrasound energy. This allows it to be specific in target tissues without damaging the adjacent structures.

The effects can be divided into thermal and non-thermal reactions on the tissues. Due to the conversion of ultrasound energy in frictional heat, it can heat up to approximately 55 C. This influences the cytoplasm and cell membrane, leading to cellular death. In post-mortem histological analyses, an “island and moat” formation was found respectively representing the coagulation necrosis and the damaged glycogen depleted cells marked for death. Within a week, phagocytic immune cells surround the damaged tissue depositing granulation and scar tissue.

The non-thermal effect is inertial cavitation created by the pulsar delivery of ultrasound waves. The pressure fluctuations lead to unstable bubble formation in the liquids, resulting in turbulence which in turn drives tissue destruction in the extracellular space.

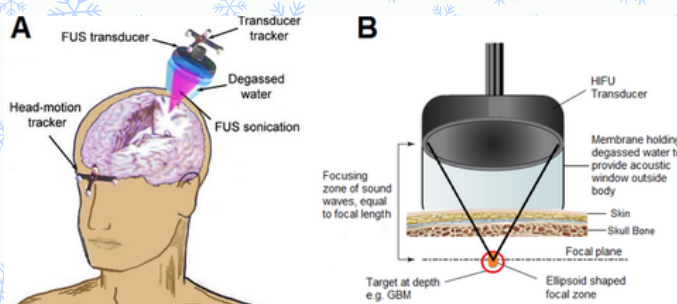
All tissues have a different attenuation coefficient; the amplitude of the energy will be diminished as its mechanical energy gets converted in heat. This is the reason it used to be necessary to remove the skull bone beforehand in the past.



## Applications of HiFU in Functional Neurosurgery

The unique aspect of this approach is its ability to be either reversible or irreversible in its effect. High-intensity focused ultrasound (HiFU), interchangeably referred to as FUS (focused ultrasound), is a precise, non-invasive option targeting structures located deep in the brain. Neurosurgical interventions such as radiofrequency ablation, radiosurgery or deep brain stimulation (DBS) provide reduction in symptoms but are invasive procedures. DBS has been known to have mechanical complications in the long term use in patients, not to mention the need to charge its battery every week. It poses a potential treatment that neither damages the surrounding tissues, uses radiation or alters the permeability of the blood-brain barrier.

Currently, HiFU is applied in the treatment of chronic neuropathic pain, essential tremor (ET), Parkinson’s Disease (PD), Obsessive-Compulsive Disorder (OCD), Major Depressive Disorder (MDD), trigeminal neuralgia, and epilepsy. Another important therapeutic advancement is its role in blood-brain barrier modification: this barrier being the main obstacle for current therapies involved in Alzheimer’s disease or cancerous processes.



**WRITTEN BY:  
ESTHER GOEDE**

## MEET THE BOARD: ERIC CHEUNG

Every month, we will highlight another member of our board, so you get to know us better. This month you can read about Dandy's Vice President; Eric Cheung!

### Getting to Know Eric

#### How old are you and how old do you feel?

I'm 20 years old, sometimes I feel 60 when I'm with my peers. At other times 15. It depends on who I'm with.

#### Which faculty are you in, and what year are you in? And what do you like most about your faculty?

LUMC third year. The focus on research. I don't like the facilities at all and there is much room for improvement when it comes to the programme, but I met some really nice people and teachers here.

#### Where are you from, and where do you currently live?

My roots are in China. I live nearby Amsterdam.

### Neurosurgical questions

#### What sparked your interest in neurosurgery?

I'm an achiever. I want to aim high. Neurosurgery is my personal goal.

#### What's your favourite brain structure and why?

Arbor vitae cerebelli. Did you read that? The name itself is glorious. And have you seen it during dissections? It's so beautiful. In fact, it is the most beautiful structure indeed.



#### You have a long surgery coming up. Which genre of music do you listen to?

Rachmaninoff piano concerto 3. Or any other (neo)romantic piano concerto.

#### If you could share one neurosurgical fact with everyone in the Netherlands, what would it be?

Awake craniotomy is the most impressive surgery.

### Joining the Dandy Netherlands Board

#### What do you enjoy the most about being the Vice President of Dandy?

Working together with my board members.

#### What made you sign up for the Dandy Board?

I like our independence and activities..

**Personal Preferences**

**If you were a superhero, what would your power be?**

Time travelling.

**What's your ultimate guilty pleasure when you're cramming for exams?**

I never cram. But I do like long study sessions in the OBA Oosterdok with a magnificent view of Amsterdam.

**What's your favourite season?**

Spring.

**Rapid Fire Round 🔥**

**Sweet or savory?**

Savory.

**Books or movies?**

Books and movies!

**Cats or dogs?**

Dogs.

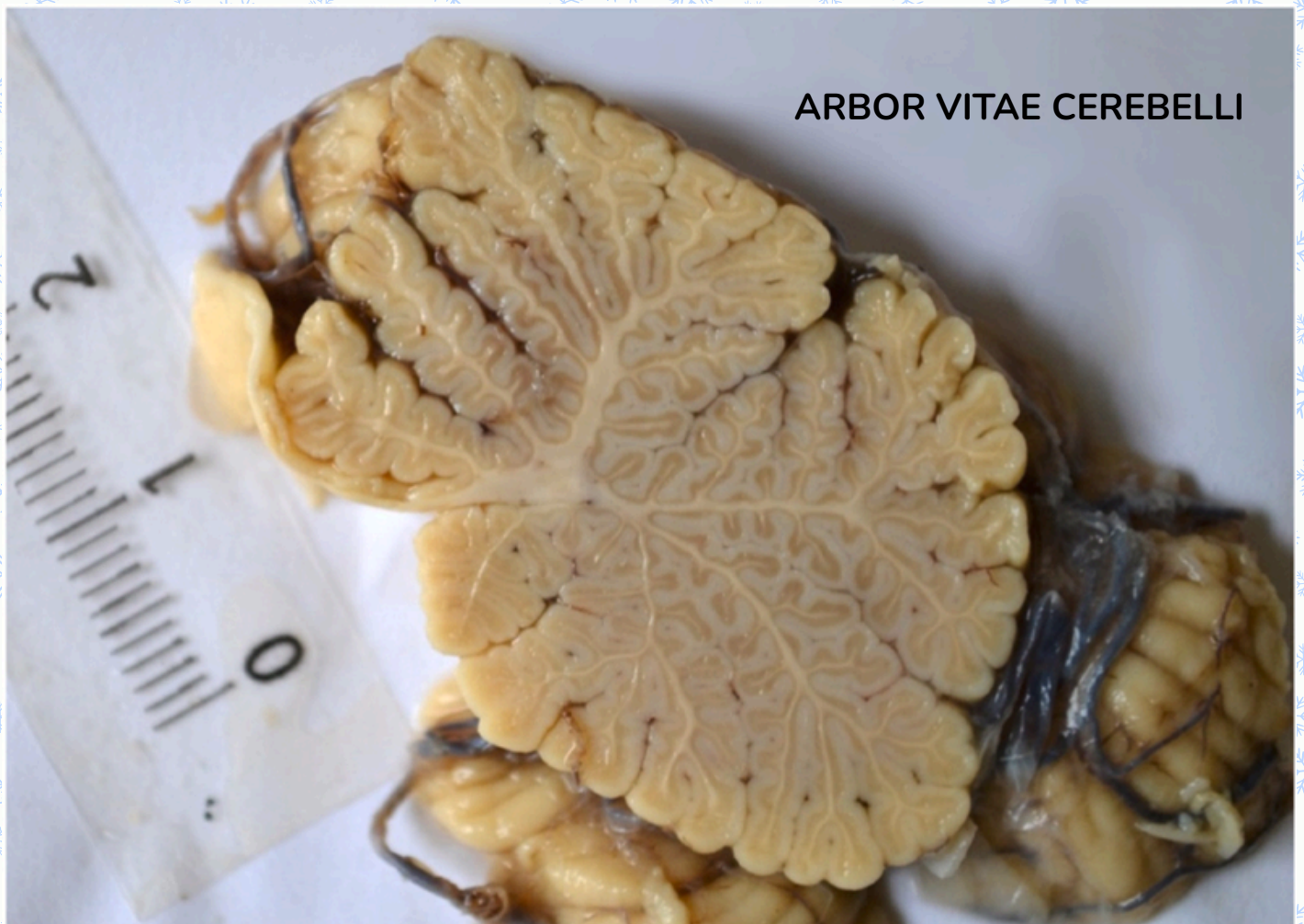**What word or phrase do you use slightly too often?**

'Like'

**Excited to meet the rest of the board?**

**Subscribe to the newsletter and tune in for upcoming editions!**

**ARBOR VITAE CEREBELLI**



## QUIZ: DANDY-EDITION WINTER 2025

**Q1: Deep Brain Stimulation (DBS) primarily works by:**

- a) Destroying the target brain tissue
- b) Electrically modulating abnormal neuronal activity
- c) Stimulating peripheral nerves
- d) Increasing dopamine release

**Q2: Which brain structure is most commonly targeted in DBS for Parkinson's disease?**

- a) globus pallidus externus
- b) Subthalamic nucleus
- c) Caudate nucleus
- d) Thalamus (VIM)

**Q3: The main indication for Gamma Knife (GK) thalamotomy is:**

- a) Parkinson's disease
- b) Epilepsy
- c) Essential tremor
- d) Cluster headache

**Q4: What is the most common side effect following subthalamic DBS?**

- a) Visual hallucinations
- b) Dysarthria or speech disturbance
- c) Complete loss of sensation
- d) Hemorrhagic stroke

**Q5: The Ventral Intermediate Nucleus (VIM) is part of which brain structure?**

- a) Thalamus
- b) Basal ganglia
- c) Cerebellum
- d) Midbrain

**ANSWERS OF THE PREVIOUS QUIZ!**

1A - 2C - 3C - 4B - 5C - 6B - 7A - 8D - 9B - 10A

**Q6: STN-DBS improves motor symptoms in Parkinson's disease primarily by affecting which abnormal brain activity?**

- a) Excess beta oscillations
- b) Reduced GABA release
- c) Increased dopamine turnover
- d) Excess gamma activity

**Q7: Which of the following is a known non-motor side effect of STN-DBS?**

- a) Diplopia
- b) Mood changes
- c) Complete hearing loss
- d) Hyperreflexia

**Q8: Gamma Knife thalamotomy for tremor targets which nucleus?**

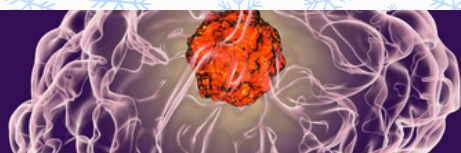
- a) STN
- b) GPi
- c) VIM
- d) Pulvinar

**Q9: In Gamma Knife thalamotomy for tremor, long-term tremor reduction is most strongly correlated with which dose-location factor?**

- a) Maximum dose exceeding 120 Gy
- b) Precise coverage of the posteroinferior VIM border
- c) Lesion volume  $>150 \text{ mm}^3$
- d) Center of dose placed  $>2 \text{ mm}$  anterior to Vc nucleus

**Q10: Which network change is most consistently associated with antidepressant response in Cg25 DBS?**

- a) Increased resting-state connectivity between Cg25 and amygdala
- b) Suppression of hyperconnectivity between Cg25 and medial prefrontal cortex
- c) Reduced thalamocortical oscillatory synchrony
- d) Increased activity in the dorsolateral prefrontal cortex during stimulation



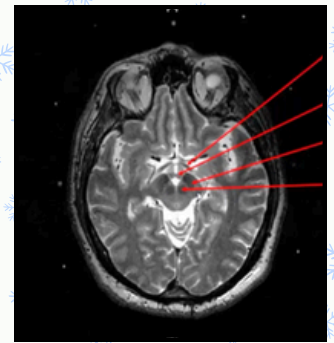
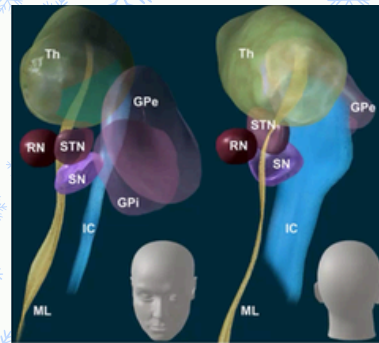
## RECAP: THE FIRST TWO LECTURES OF THE ACADEMIC YEAR

We kicked off the new academic year with two inspiring lectures in neurosurgery — each offering a unique perspective on this diverse and constantly evolving specialty.

### Functional Neurosurgery - Dr. Hilko Ardon

Our first lecture was delivered by Dr. Hilko Ardon, neurosurgeon at the ETZ and JBZ hospitals. He introduced us to the field of functional neurosurgery, where technological innovation and microsurgical precision come together.

Topics such as Deep Brain Stimulation (DBS) were discussed in depth, giving students a clear view of the complex decision-making and refined techniques that define this subspecialty. The lecture provided valuable insights into how cutting-edge neuroscience is translated into clinical practice.



### Oncological neurosurgery - Sterre Joor (AIOS)

The second lecture, organized in collaboration with VCMS Amsterdam, focused on oncological neurosurgery. Sterre Joor guided us through the neuroanatomy, etiology, and epidemiology of brain tumors.

Through impressive case presentations and surgical imaging, she demonstrated the challenges and considerations involved in tumor surgery — as well as the profound impact a brain tumor diagnosis can have on patients and their families.

Together, these two sessions offered a rich and inspiring beginning to the academic year. They showcased how neuroanatomy, technology, and clinical judgment come together within neurosurgery, and highlighted the breadth of this dynamic field.

We proudly look back on these afternoons filled with innovation, interaction, and inspiration. Our sincere thanks to Hilko Ardon and Sterre Joor for sharing their expertises!



**WRITTEN BY:  
JOOST BERTENS**

## STAY TUNED FOR THE 2025-2026 DANDY PROGRAMME

- UPCOMING EVENT -

### VASCULAR NEUROSURGERY



Erasmus MC

*Erasmus*

Dr. Ruben Dammers will take you into one of the most intense moments in neurosurgery: operating on an intracerebral hemorrhage. When a deep vessel ruptures, surgeons have to act fast — deciding if, when, and how to intervene.

We break down the key surgical approaches, the real challenges in the OR, and what happens when every minute matters. This will be a sharp, fast-paced look at one of the most dramatic procedures in the field.

**WHEN?** 21ST JANUARY 19:00

**WHO?** DR. RUBEN DAMMERS

**WHERE?** ERASMUS MC, ROTTERDAM

#### NEXT ISSUE:

---

A DEEP-DIVE INTO THE  
HISTORY OF NEUROSURGERY

---

NEW BRAINTEASER

---

RECAP OF PAST EVENTS

---

FUTURE EVENTS

---

QUIZ ANSWERS AND MORE  
FROM THE NEW BOARD!

---

STAY UP-TO-DATE WITH DANDY  
NETHERLANDS AND FOLLOW US  
ON SOCIAL MEDIA:



[www.dandynetherlands.nl](http://www.dandynetherlands.nl)



[dandynetherlands](https://www.instagram.com/dandynetherlands)



Dandy Netherlands  
Neurosurgical Club

ARE YOU INTERESTED IN A COLLABORATION  
WITH DANDY NETHERLANDS? CONTACT US  
VIA EMAIL:

[INFO@DANDYNETHERLANDS.NL](mailto:INFO@DANDYNETHERLANDS.NL)